

# Bronchial foreign body removal under general anesthesia with a modified port, a fogarty balloon catheter and a grasping forceps

Sang Ho Lim, Dong Kyu Lee, and Jea Yeun Lee

Department of Anesthesiology and Pain Medicine, Korea University Medical Center, Guro Hospital, Seoul, Korea

This report describes two cases of bronchial foreign body removal in small children. The procedure differs from previous reports because a modified port was used for continuous ventilation, making the procedure safer by preventing hypoxemia and airway edema. Additionally, grasping forceps was used with a Fogarty balloon catheter to retrieve the foreign body, reducing damage to the airway mucosa and vocal cords. Finally, the procedure was performed by anesthesiologists, who are airway manipulation experts.

## Case 1

A 20-month-old boy, weighing 12.5 kg, was admitted to the hospital due to cyanosis and a persistent cough following ingestion of a peanut. Upon arrival at the hospital, his arterial blood gas analysis (ABGA) revealed the following results: pH 7.24, PCO<sub>2</sub> 58 mmHg, PO<sub>2</sub> 50 mmHg, oxygen saturation 77%, and his chest X-ray showed air trapping in the left lung, suggesting a check-valve obstruction. His past history and lab test results were unremarkable.

Emergency rigid bronchoscopy was performed under general anesthesia. Anesthesia was induced with thiopental (50 mg) and rocuronium (7 mg); it was maintained with 50% oxygen, 50% nitrous oxide, and sevoflurane. The patient's initial oxygen saturation was 80%, but after intubation and 100% oxygen administration, the saturation level increased to 100%. Even when 50% oxygen was applied, the saturation was 100%. The

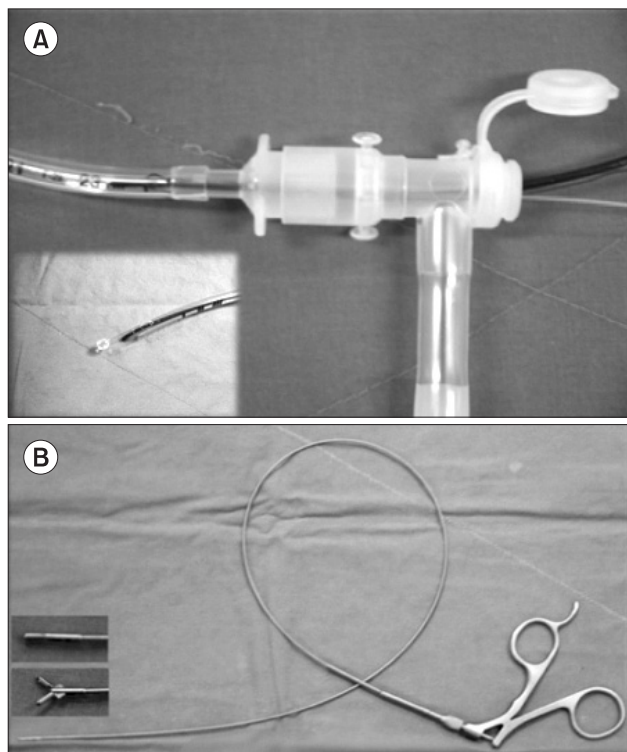
oncall otolaryngologist identified peanut pieces at the carina and at the right main bronchus by rigid bronchoscopy (Doesel-Huzly bronchoscope, size 3 and 3.5, Karl Storz GmbH & Co. KG, Tuttlingen, Germany), and the pieces were removed using forceps. The ventilation port was opened to introduce the forceps, and during the apnea period, which lasted for 10–15 s, the oxygen saturation dropped to 80%. A rigid bronchoscopic examination performed after foreign body removal revealed no residual peanut pieces, and the patient was intubated with an endotracheal tube (ID 4.0 Sheridan<sup>®</sup> uncuffed<sup>™</sup>, Teleflex Medical, Durham, USA). Oxygen saturation remained at 99% during the remainder of the procedure.

However, 2 days later, the patient was still coughing and developed a mild fever. Follow-up chest radiographs showed unresolved air trapping and pneumonia in the left lung. A computed tomography (CT) scan revealed a low-density lesion in the left main bronchus. The patient was referred to our department, and an airway exploration with flexible bronchoscopy (size 1.8 mm LF-P, intubation fiberscope, Olympus, Shinjuku-ku, Tokyo, Japan) under general anesthesia was planned. After preoxygenation with 100% oxygen, general anesthesia was induced with thiopental (50 mg) and rocuronium (7 mg). A slightly large ETT (ID 5.0 Sheridan Sheridan<sup>®</sup> uncuffed<sup>™</sup>, Teleflex Medical, Durham, USA) was chosen for the procedure. A modified connector with two ports was attached to the ETT which allowed the passage of instruments with no interruption in ventilation (Fig. 1). Flexible

---

Corresponding author: Sang Ho Lim, M.D., Ph.D., Department of Anesthesiology and Pain Medicine, Korea University Medical Center, Guro Hospital, Guro 2-dong, Guro-gu, Seoul 152-703, Korea. Tel: 82-2-2626-1437, Fax: 82-2-851-9897, E-mail: Lsh1102@unitel.co.kr

© This is an open-access article distributed under the terms of the Creative Commons Attribution Non-Commercial License (<http://creativecommons.org/licenses/by-nc/3.0/>), which permits unrestricted non-commercial use, distribution, and reproduction in any medium, provided the original work is properly cited.



**Fig. 1.** (A) A modified connector is connected to the ETT to allow easy passage of instruments while simultaneously providing adequate ventilation. Also, a 3-Fr Fogarty embolectomy catheter, introduced with a flexible bronchoscope, can be seen. The balloon of the Fogarty catheter was dilated with saline, and it was used to pull the foreign body out. (B) 5-Fr flexible foreign body grasping forceps have a blunted tip, allowing for a less traumatic procedure. It is generally used for ureteral stone removal in the clinical setting.

bronchoscopic exam by anesthesiologists revealed a remnant foreign body at the distal end of the left main bronchus. A Fogarty balloon catheter (3-Fr arterial embolectomy catheter, Edwards Lifesciences Corporation of Puerto Rico, Irvine, CA, USA) was then tied to the flexible bronchoscope and passed through a slit between the foreign body and the bronchial wall. The Fogarty catheter balloon was dilated with 0.6 ml of saline and used to gently pull the foreign body toward the carina. The foreign body was removed with grasping forceps (5-Fr Richard Wolf Medical instruments Co., Vernon Hills, IL, USA). There was no interruption in ventilation during the procedure. The patient's oxygen saturation was maintained at 99%, and the end tidal carbon dioxide was maintained at about 35 mmHg. The initial airway pressure was 12 mmHg, and increased to 18 mmHg when instruments were introduced into the ETT. The diameter of the ETT, flexible bronchoscope, Fogarty catheter and grasping forceps were 5 mm, 1.8 mm, 1 mm, and 1.67 mm, respectively. The patient was treated with antibiotics and discharged 13 days later with no complications.

## Case 2

A 13-month-old boy, weighing 8.4 kg, was hospitalized after aspirating a nut. His chest radiograph showed expiratory air trapping in the left lung, and a CT scan revealed a 4-mm foreign body at the left main bronchus. His initial ABGA findings included: pH 7.48;  $PCO_2$  27.9 mmHg;  $PO_2$  70.2 mmHg; and oxygen saturation 94.5%. Emergency flexible bronchoscopy under general anesthesia was planned. Anesthesia was induced with thiopental (50 mg) and rocuronium (5 mg). The patient was intubated with an ETT (ID 4.5 Sheridan Sheridan<sup>®</sup> uncuffed<sup>™</sup>, Teleflex Medical, Durham, USA), and controlled ventilation was maintained. The same procedure described in the first case was performed, and the foreign body was removed successfully. During the procedure, his saturation was maintained at 100%, airway pressure was below 20 mmHg, and the end tidal carbon dioxide was maintained at about 30 mmHg.

## Discussion

In small children, the removal of an aspirated foreign body by rigid bronchoscopy is a potentially risky procedure with the possibility of foreign body dislocation and interrupted ventilation, leading to arterial hypoxemia, bradycardia, and cardiac arrest [1-5]. Also, the shape of the rigid bronchoscope makes it nearly impossible to examine structures distal to the carina, thus limiting its role in foreign body removal because foreign bodies are commonly wedged distal to the carina.

This procedure combines various different types of equipment together to enable foreign body removal in a safer manner. A modified connector allows continuous ventilation, thus preventing hypoxemia during the procedure and providing more time for the procedure to be performed. A Fogarty balloon catheter enables impacted foreign bodies to be removed, and grasping forceps prevents further damage to the mucosa and vocal cords.

We believe that the use of a flexible FOB, a Fogarty balloon catheter, flexible grasping forceps, and a modified connector together to remove foreign bodies allows for a safer and more precise procedure because continuous ventilation and direct visualization of the distal bronchus is possible using this method. Also, anesthesiologists are uniquely qualified to perform this procedure because they are experts in airway management.

## References

1. Metrangelo S, Monetti C, Meneghini L, Zadra N, Giusti F. Eight years' experience with foreign-body aspiration in children: what is really important for a timely diagnosis? *J Pediatr Surg* 1999; 34:

- 1229-31.
2. Jiaqiang S, Jingwu S, Yanming H, Qiuping L, Yinfeng W, Xianguang L, et al. Rigid bronchoscopy for inhaled pen caps in children. *J Pediatr Surg* 2009; 44: 1708-11.
  3. Zhijun C, Fugao Z, Niankai Z, Jingjing C. Therapeutic experience from 1428 patients with pediatric tracheobronchial foreign body. *J Pediatr Surg* 2008; 43: 718-21.
  4. Tomaske M, Gerber AC, Weiss M. Anesthesia and periinterventional morbidity of rigid bronchoscopy for tracheobronchial foreign body diagnosis and removal. *Paediatr Anaesth* 2006; 16: 123-9.
  5. Ciftci AO, Bingöl-Koloğlu M, Senocak ME, Tanyel FC, Büyük-pamukçu N. Bronchoscopy for evaluation of foreign body aspiration in children. *J Pediatr Surg* 2003; 38: 1170-6.