

# Shearing of an intrathecal catheter during insertion for cerebrospinal fluid drainage

Jae Jun Lee, Gi Ho Gim, Ji Su Jang, and Sung Mi Hwang

Department of Anesthesiology and Pain Medicine, School of Medicine, Hallym University, Chuncheon, Korea

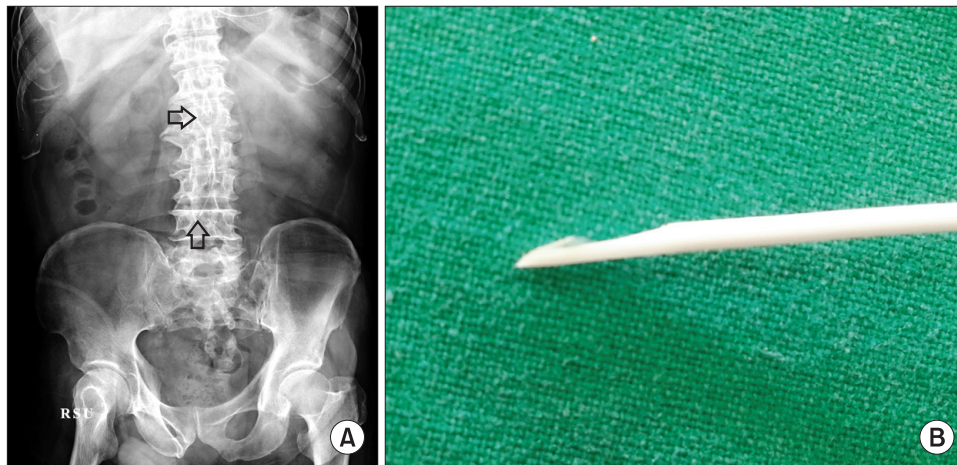
Intrathecal catheters have been placed for the management of a wide range of medical and surgical conditions [1]. As the use of intrathecal catheters increases, surgeons and anesthesiologists must be made aware of possible complications related to their placement, including infection, headache, pneumocephalus, cerebrospinal fluid (CSF) leakage, neuroaxial hematoma, intracranial hemorrhage, and catheter fracture [2,3]. Breakage or shearing of a catheter is rare or under-reported, with an incidence rate of 0 to 3.3% [2,4].

We present a case of intrathecal catheter shearing and fragmentation during insertion, while turning the catheter clockwise through a Tuohy needle for lumbar CSF drainage, and the subsequent surgical removal of the fragment.

A 74-year-old man, 160 cm tall and weighing 65 kg, un-

derwent a decompressive craniectomy due to malignant brain edema caused by left middle cerebral artery area infarction. He had right hemiplegia and atrial fibrillation. Two months later, cranioplasty was done for a skull defect, and the surgery was uneventful. Three days later, CSF leakage was observed on brain computed tomography. To promote dural healing, closed continuous lumbar drainage of the CSF was indicated.

It was difficult to assume an optimal position for lumbar puncture because of the patient's hemiplegia. The patient was placed in the left lateral decubitus position with flexion of the left hip and knee. A 14 G Tuohy needle was inserted into the L3-4 intervertebral space without difficulty, obtaining free-flowing CSF. As there was some resistance encountered during advancement of the catheter 8 cm beyond the tip of the needle



**Fig. 1.** (A) Radiograph showing the retained intrathecal catheter (arrows). (B) Catheter, sheared diagonally.

Corresponding author: Sung Mi Hwang, M.D., Department of Anesthesiology and Pain Medicine, School of Medicine, Hallym University, 77, Sakju-ro, Chuncheon 200-704, Korea. Tel: 82-33-240-5155, Fax: 82-33-251-0941, E-mail: h70sm@hallym.or.kr

© This is an open-access article distributed under the terms of the Creative Commons Attribution Non-Commercial License (<http://creativecommons.org/licenses/by-nc/3.0/>), which permits unrestricted non-commercial use, distribution, and reproduction in any medium, provided the original work is properly cited.

into the subarachnoid space, the catheter was turned clockwise through the needle. It snapped suddenly. After the Tuohy needle and catheter were withdrawn, lumbar spine radiography revealed a catheter fragment in the L2–L4 subarachnoid space (Fig. 1A). Although the patient did not show neurological symptoms and pain, it was decided that to allow the dura to heal, the fragment must be surgically removed.

Under general anesthesia, partial hemilaminectomy at the L2–4 was performed, and the catheter fragment was removed without difficulty. The length of the diagonally sheared fragment was about 9.4 cm (Fig. 1B). Another catheter was placed under direct visualization at one level higher than that site. The free flow of CSF was obtained from the catheter, and the completion of the surgery was uneventful. The second catheter was removed 3 days later. The patient experienced no further complications related to lumbar draining, and he was discharged.

A Hermetic™ Lumbar Drainage Accessory kit (Integra Neurosciences, Plainsboro, NJ, USA) contains a 14 G Tuohy needle (9 cm) and an 80 cm Hermetic lumbar drainage catheter (0.7 mm ID, 1.5 mm OD). The Tuohy needle has a sharp-edged tip. The intrathecal siliconized catheter is larger and softer than an epidural catheter and is used to reduce damage to the spinal cord/nerve root [4]. But it can be difficult to advance the catheter through a Tuohy needle into the subarachnoid space. In addition, the ideal length of an intrathecal catheter in the subarachnoid space is 8–10 cm, to minimize the chance that the catheter will be inadvertently pulled out with patient movement [2]. Most cases of retained intrathecal catheters are associated with difficulty inserting or advancing the catheter [1,4].

Olivar et al. [4] proposed mechanisms by which a catheter may be broken by excessive force or stretching, sheared by the Tuohy needle, or both. A catheter can fracture during intentional or accidental retraction through the needle during placement and can be sheared by the sharp edge of the Tuohy needle, the incorrect use of the guide wire, or the use of excessive force.

In addition, decreased durability of a catheter owing to damage caused by the needle edge or cutter during insertion can cause problems during its removal [5]. In our case, the catheter was sheared off as it was turned clockwise through the Tuohy needle. Based on our experience, a catheter never be turned in the Tuohy needle after it has been inserted beyond the needle tip and there is difficulty encountered advancing the catheter. When insertion is difficult, it is better to remove the Tuohy needle and catheter together. In addition, poor patient positioning was thought to be one cause of difficult catheter insertion in our case. Breakage or shearing of an intrathecal catheter also can occur during removal. Optimal patient positioning during removal is just as critical as during insertion, and excessive force should be avoided as it can cause stretching and breakage of the catheter.

Guidelines for the management of retained intrathecal lumbar catheter are not widely available. Management must be individualized according to scheduled surgery, patient's comorbidities, infection risk, catheter location/migration, fragment size, patient wishes, and presence of neurological symptoms [3,4]. When managed conservatively, periodic patient follow-up with imaging is essential due to possible fragment migration [1].

In the case presented here, the retained catheter was surgically removed. Although the patient had no neurological symptoms, fragment removal was necessary to allow the dura to heal. On lumbar spine radiography, the fragment appeared to be easily removable, so surgery was performed.

In summary, to prevent breakage or shearing of intrathecal catheters during insertion, we recommend that it should be performed by an expert in this technique and not be withdrawn or turned through the needle after it has been inserted into the subarachnoid space beyond the needle tip and removed simultaneously with the needle and not be reinserted, even when it appears to be intact, as it may be damaged by withdrawal through the Tuohy needle.

## References

1. Forsythe A, Gupta A, Cohen SP. Retained intrathecal catheter fragment after spinal drain insertion. *Reg Anesth Pain Med* 2009; 34: 375-8.
2. Fedorow CA, Moon MC, Mutch WA, Grocott HP. Lumbar cerebrospinal fluid drainage for thoracoabdominal aortic surgery: rationale and practical consideration for management. *Anesth Analg* 2010; 111: 46-58.
3. Açıkbaş SC, Akyüz M, Kazan S, Tuncer R. Complications of closed continuous lumbar drainage of cerebrospinal fluid. *Acta Neurochir (Wien)* 2002; 144: 475-80.
4. Olivar H, Bramhall JS, Rozet I, Vavilala MS, Souter MJ, Lee LA, et al. Subarachnoid lumbar drains: a case series of fractured catheters and a near miss. *Can J Anaesth* 2007; 54: 829-34.
5. Collier C. Epidural catheter breakage: a possible mechanism. *Int J Obstet Anesth* 2000; 9: 87-93.