

Urgent craniectomy for subdural hematoma in the 8-month-old infant with unrecognized hemophilia B

Jong Bun Kim¹, Hyun-Ju Jung¹, Kyong Shil Im¹, Sang Woo Han¹, and Sang-Hun Lee²

¹Department of Anesthesiology and Pain Medicine, College of Medicine, The Catholic University of Korea, Uijeongbu St Mary's Hospital, Uijeongbu, ²Department of Obstetrics and Gynecology, College of Medicine, University of Ulsan, Ulsan University Hospital, Ulsan, Korea

Intracranial hemorrhage (ICH) is an uncommon manifestation of hemophilia that presents childhood. ICH in hemophilic children is usually preceded by head trauma [1]. We present the case of a male 8-month-old infant patient that had undergone an urgent craniectomy for subdural hematoma without an established hemophilia diagnosis. The purpose of this report is to emphasize the importance of a thorough personal and familial history, especially, in urgent circumstances and the necessity of considering hemophilia as a cause of traumatic ICH.

A male 8-month-old infant that weighed 9.5 kg presented to the emergency department with a chief complaint of stuporous mentality. In the morning of the day of admission, he visited a local clinic due to an increased irritability, but was discharged without specific management. Several hours later, the infant showed signs of drowsiness, increasing lethargy and stuporous mentality. The child had fallen from a chair one week prior to admission. The patient's past medical history was unspecific and at the time the familial history was not assessed.

On arrival at the ER, the Glasgow Coma Scale was 11/15 (E3V3M5) and he had a right hemiparesis (grade 2/5) and anisocoria. The vital signs were blood pressure of 90/60 mmHg, heart rate of 130 beats/min, respiratory rate of 30 beats/min, and percutaneous oxygen saturation of 99%. The head computed tomographic scan revealed a subdural hematoma along the left lateral cerebral convexity with a midline shift and compression of the underlying brain parenchyma (Fig. 1). The

hemoglobin level, hematocrit level and platelet count were 8.1 g/dl, 24.6% and 235,000/mm³, respectively. The prothrombin time (PT) and APTT was performed but the results had not yet been reported. Due to the patients rapid deterioration, an urgent burr hole procedure was performed before the blood test results were verified. Anesthesia was induced by the administration of pentothal sodium 50 mg, and fentanyl 15 mcg.

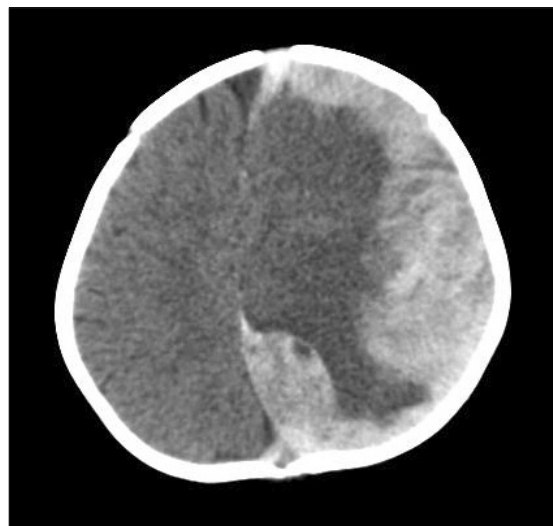


Fig. 1. Head computed tomographic scan shows subdural hematoma along the left lateral cerebral convexity with a midline shift and the compression of underlying brain parenchyma.

Corresponding author: Kyong Shil Im, M.D., Department of Anesthesiology and Pain Medicine, College of Medicine, The Catholic University of Korea, Uijeongbu St Mary's Hospital, 65-1, Geumo-dong, Uijeongbu 480-137, Korea. Tel: 82-31-820-3087, Fax: 82-31-821-8449, E-mail: idonga@catholic.ac.kr

© This is an open-access article distributed under the terms of the Creative Commons Attribution Non-Commercial License (<http://creativecommons.org/licenses/by-nc/3.0/>), which permits unrestricted non-commercial use, distribution, and reproduction in any medium, provided the original work is properly cited.

Then endotracheal intubation was facilitated by rocuronium 5 mg. Anesthesia was maintained with sevoflurane-N₂O-O₂. The surgeon failed to aspirate the hematoma through the burr hole therefore the surgeon performed a craniotomy to evacuate the hematoma. He showed the excessive bleeding from the wound. Twenty minutes after the surgery started, the abnormal APTT finding was reported. PT, INR and APTT were 12.6 sec (normal; 11.1–13.1), 1.08 (normal; 0.9–1.12) and 93.5 sec (normal; 21.0–38.0), respectively. At that moment, hemophilia was suspected and a thorough and detailed medical and family history took place. It was found that the child's maternal uncle had hemophilia. The excessive bleeding had continued during operation. The bone flap was not replaced because of the brain swelling. Total anesthesia duration was 120 min. The total blood loss was approximately 500 ml. The infant was transfused with 1 unit of fresh frozen plasma (FFP) and 1 unit of packed red blood cells. Coagulation factors assays were performed immediately following the operation and these results were: factor V = 52%, factor VII = 68%, factor VIII = 106%, factor IX = 84%, factor X = 64%, factor XI = 85%, factor XII = 45%, and factor XIII = present. PT, INR and APTT were 13.1 sec (normal; 11.1–13.1), 1.12 (normal; 0.9–1.12) and 35.4 sec (normal; 21.0–38.0), respectively. However, the postoperative bleeding occurred intermittently from craniectomy incision sites. The infant was administered 1 unit of cryoprecipitate every 8 to 12 hours and 1 unit of FFP. The coagulation factor, PT, APTT and assays were monitored periodically. The infant had a recurrent bleed and underwent a craniectomy on the 3rd and the 11th postoperative day. The levels of coagulation factors VIII, IX, and XI assays, which were done on the 16th postoperative day were 147%, 2%, and 86%, respectively. The infant was diagnosed with moderate hemophilia B. Since then, transfusion of cryoprecipitate and FFP was stopped and the recombinant coagulation factor IX (Benefix inj[®]) 270 IU every 12 hours for 10 days was administered, followed by the administration of the recombinant coagulation factor IX 270 IU every day for 2 weeks. However, the infant eventually had a poor outcome and remained in right hemiparesis and developmental delay at the age 3 years and 7 months.

Hemophilia is a hereditary X-linked bleeding disorder characterized by impaired blood coagulation. Hemophilia occurs in 1 : 10,000 male births; approximately 85% have hemophilia A and about 15% have hemophilia B [1].

ICH is an uncommon presenting manifestation of hemophilia in childhood [1]. However, it represents the main cause of death in hemophilic patients and is responsible for 75% of neurological sequelae among survivors [2]. Although

spontaneous ICH may occur in patients with severe hemophilia, minor trauma is the most common cause of ICH in hemophilic children and is often neglected [3]. In addition, symptoms of a subdural hematoma, which often occur soon after trauma, may be delayed for several weeks [4]. Therefore, the possibility of ICH should neither be excluded on the basis of the absence of head trauma history nor on the absence of sign. The possibility of hemophilia should be considered as a cause of ICH from a minor trauma in an infant.

The aim of preoperative coagulation testing is to detect a patient's characteristics that may be associated with increased perioperative bleeding. The preoperative assessment of bleed history of the patient and of his/her relatives remains the most important tool for the detection of both mild and severe inherited or acquired bleeding disorders [5]. The reported result of the routine coagulation test is generally made available with a delay of at least 30–60 min [5]. Due to the urgent presentation requiring a craniectomy, we did not wait for the preoperative coagulation test results in the present case. An error was made of not assessing the familial history for hemophilia and not considering hemophilia as a cause of traumatic ICH.

In conclusion, we always should be aware that the preoperative assessment of bleeding history of the patient and of his/her relatives is the most important tool for detection of bleeding disorders. In addition, we emphasize that the thorough and detailed personal and familial history taking, especially, in urgent circumstances is very important. Finally, we must consider the possibility of hemophilia as a cause of traumatic ICH.

References

1. Bladen M, Khair K, Liesner R, Main E. Long-term consequences of intracranial haemorrhage in children with haemophilia. *Haemophilia* 2009; 15: 184-92.
2. Klinge J, Auberger K, Auerswald G, Brackmann HH, Mauz-Korholz C, Kreuz W. Prevalence and outcome of intracranial haemorrhage in haemophiliacs--a survey of the paediatric group of the German Society of Thrombosis and Haemostasis (GTH). *Eur J Pediatr* 1999; 158 Suppl 3: S162-5.
3. Martinowitz U, Heim M, Tadmor R, Eldor A, Rider I, Findler G, et al. Intracranial hemorrhage in patients with hemophilia. *Neurosurgery* 1986; 18: 538-41.
4. Papiroglu T, Ozdemir MA, Unal E, Altuner Torun Y, Coskun A, Menku A, et al. Intracranial hemorrhage in children with congenital factor deficiencies. *Childs Nerv Syst* 2011; 27: 1963-6.
5. Kozek-Langenecker SA. Perioperative coagulation monitoring. *Best Pract Res Clin Anaesthesiol* 2010; 24: 27-40.