대한마취과학회지 2008; 54: 446～8
Korean J Anesthesiol Vol. 54, No. 4, April, 2008

□ 증례보고 □

Combined Spinal-epidural Anesthesia in a Patient with Severe Thoracic Kyphoscoliosis

—A case report—

Department of Anesthesia and Pain Medicine, SanggyePaik Hospital, College of Medical, Inje University, Seoul, Korea

Oksun Kim, M.D., **Sang-seock Lee**, M.D., **Tae-Joong Yoo**, M.D., **Yun-Hee Lim**, M.D., and **Jun Heum Yon**, M.D.

Kyphoscoliosis is a deformity of the costovertebral skeletal structures characterized by an anterior flexion (kyphosis) and lateral curvature (scoliosis) of the patient's vertebral column.[1] In kyphoscoliosis, lung volume and compliance is reduced due to the change of vertebral column. The work of breathing is increased by abnormal mechanism of the thorax and by increased airway resistance resulting from small lung volume. Airway management and respiratory problems are common and spinal deformities can cause difficulties with regional anesthesia. We had experienced a successful spinal anesthesia for closed reduction and internal fixation (CRIF) and proximal femoral nail (PFN) of fractured intertrochanteric femur in a patient with extremely severe thoracolumbar kyphoscoliosis. **(Korean J Anesthesiol 2008; 54: 446～8)**

Key Words: combined spinal-epidural anesthesia, intertrochanteric fracture of femur, kyphosis, scoliosis.

CASE REPORT

A male patient, 66 years old, 160 cm tall, weighing 40 kg, was admitted to a local clinic for his fractured intertrochanteric femur resulting from the crash against a vehicle. The next day, he was transferred to our hospital and was scheduled for closed reduction and internal fixation (CRIF) and proximal femoral nail (PFN).

On the day of hospitalization, body temperature was 37 degrees centigrade, blood pressure was 110-120/80-90 mmHg. Hip spica splint was applied to the fractured right intertrochanteric femur.

According to his medical history, the kyphoscoliosis was already diagnosed when he was about 5 years old, was left untreated. He did not cough and have any sputum but complained of dyspnea on exertion. On the physical test, the breathing sound was clear. Rale and wheezing was not heard. There was not any active lung lesion on chest X ray, but severe thoracic kyphoscoliosis was found. According to Cobb's angle, the lateral angle was 50 degrees and posterior angle was 125 degrees (Fig. 1). In the arterial blood gas test on room air, he showed compensated respiratory acidosis (pH 7.385, $PaCO_2$ 55.2 mmHg, PaO_2 73.3 mmHg, HCO_3 32.3 mmol/L). Pulmonary function test could not be done because

Fig. 1. Surgical position of the patient. This figure is showing the severity of the patient's kyphoscoliosis.

Received : October 12, 2007
Corresponding to : Sang-seock Lee, Department of Anesthesia and Pain Medicine, SanggyePaik Hospital, 761-1, Sanggye 7-dong, Nowon-gu, Seoul 139-707, Korea. Tel: 82-2-950-1173, Fax: 82-2-950-1323, E-mail: sslee@sanggyepaik.ac.kr

the patient was in a bed-ridden state. On the blood test before surgery, Hb was 10.5 g/dL and Hct was 32.7%.

We decided to apply regional anesthesia in order to reduce the risk of postoperative pulmonary complication that may be caused by general anesthesia. Overall, he strongly rejected getting general anesthesia. We concluded that it would better to do regional anesthesia, especially combined spinal-epidural anesthesia on lumbar vertebrae even though severe kyphoscoliosis and spinal stenosis.

Intraoperative monitoring included 5-lead ECG, pulse oximetery. A radial arterial cannula was inserted for intermittent blood gas determinations and for continuous monitoring of arterial blood pressure.

The circulation was preloaded with 400 mL of lactated Ringer's solution. For combined spinal-epidural anesthesia (Espocan®, B. Broun, Germany), the patient was placed in a right lateral decubitus position. After local anesthetic infiltration, a 17-gauge Tuohy needle was inserted at the lumbar 3–4 level. The epidural space was identified by loss of resistance. We also confirmed location and direction of needle by C-Arm (Fig. 2, 3). The 25-guage Whitacare needle was inserted and slowly advanced toward the dura. The subarachnoid space was reached after the needle had been moved 4.5 cm. An intrathecal 6 mg 0.5% hyperbaric bupivacaine (Marcaine 0.5% heavy (AstraZeneca, Sweden)) was injected and epidural catheter is inserted into epidural space. Afterward, the patient was immediately turned to supine position.

7 minutes after intrathecal injection, the level of anesthesia was T6. As blood pressure dropped down to 85/45 mmHg just after the anesthesia, patient complained of nausea. Fluid was administrated quickly and ephedrine (5 mg and 10 mg) was injected into IV line, repeatedly. Blood pressure was restored to 110–130/70–80 mmHg and patient did not feel nausea anymore. There was no need for antiemetic. At this moment, heart rate was 95–105 bpm and O_2 saturation was 100%, measured by pulse oximetery. During the surgery, we provided oxygen at the rate of 3 L per minute through nasal cannula, and the arterial blood gas analysis is pH 7.383 - $PaCO_2$ 53.2 mmHg - PaO_2 104.3 mmHg - HCO_3 31 mmol/L. Hb and Hct was 7.6 g/dL and 22%.

About 10 minutes after the surgical procedure, 1 unit of packed red blood cells (packed RBC) was infused to correct anemia. The surgery took 90 minutes. During the surgery, blood pressure was maintaining 120–150/80–100 mmHg, heart rate was maintaining 90–105 bpm, O_2 saturation remained 100% steadily, and there was no symptom of dyspnea. Anesthesia was maintained at the level of T12, 80 minutes after anesthesia. At 120 minutes after anesthesia, we checked up the recovery of sensory and motor nerve completely.

After the surgery, the patient was conveyed to recovery room, and we stopped O_2 supply. While staying in the recovery room for about 1 hour and half, the patient maintained O_2

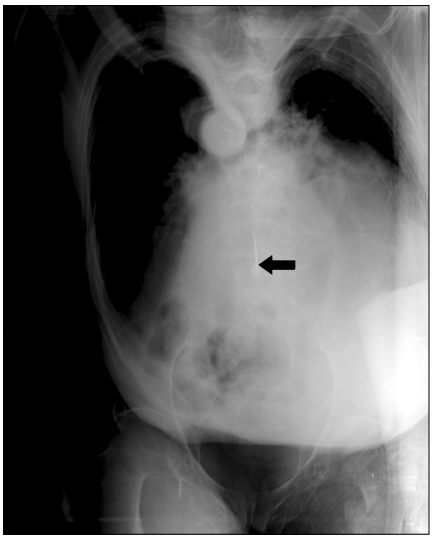

Fig. 2. The AP (anterior-posterior) radiographic view of lumbar-sacral region. The black arrow is indicating a Tuohy needle for epidural anesthesia.

Fig. 3. The lateral radiographic view of lumbar-sacral region. The black arrow is indicating a Tuohy needle for epidural anesthesia.

saturation of 97%, the blood pressure of 120−150/70−90 mmHg and the heart rate of 90−105 bpm. At the same time, the arterial blood gas analysis is pH 7.402 - $PaCO_2$ 45.5 mmHg - PaO_2 85.6 mmHg - HCO_3 27 mmol/L. Before discharging recovery room, his epidural catheter was removed because we worried that epidural opioid would cause respiratory depression. We planned to give more safe drugs such as acetaminophen per orally for his postoperative pain control. The patient was conveyed to general ward and satisfied with his pain relief.

DISCUSSION

Kyphoscoliosis is a disorder characterized by progressive deformity of spine consisting of lateral and posterior curvatures. In majority it is of idiopathic etiology, which account for 80% of case. Kyphoscoliosis commonly begins during late childhood and progresses in severity during periods of rapid skeletal growth.

The level of derangements in cardiac and pulmonary function of kyphoscoliosis patient is related to the amount of Cobb's angle in thoracolumbar X-ray. If this angle is larger than 40 degrees the cardio-pulmonary function frequently decreases, and if larger than 100 degrees, it significantly decreases.[2,3] In addition, considering only scoliosis, if the angle is smaller than 60 degrees the decrease of the efficiency of pulmonary function is frequent. It is said that the angle larger than 100 degrees can cause significantly low efficiency of cardiac and pulmonary function, but another report argues that there seems no relation between them.[4,5] In our case, according to Cobb's angle, lateral angle is 50 degrees and posterior angle is 125 degrees. And the spinal column level affected by scoliosis may cause the decrease of efficiency of cardiac and pulmonary function.

The change of pulmonary function, which is distinctive for kyphoscoliosis patient, is the restrictive pulmonary insufficiency in which residual volume is maintained and the total lung volume and vital capacity decreases. Moreover, the compliance of lung decreases and the work of breathing gets bigger and the tidal volume and breathing decreases for the deformation of chest wall that presses the lung. Overall, this causes hypoventilation and ventilation-perfusion mismatch. The deformation of chest prevents the development of pulmonary vascular system, which causes the pulmonary vascular resistance to increase by pulmonary vascular constriction.[6] This causes pulmonary hypertension and right heart failure, and if it is severe, it is possible for cor pulmonale to occur, and in fact, this is the major cause of death.

On the other hand, it is hard to perform spinal or epidural anesthesia in kyphoscoliosis patient because of spinal deformity and spinal stenosis. Accordingly, it is most important to evaluate fully about it and discuss about what kind of anesthesia to perform. In this case, however, the spinal-epidural anesthesia was operated because the pulmonary function test was not easy for the patient's bed-ridden state and as well as the patient's strong rejection for general anesthesia. The advantage of this technique is that it provides rapid onset of dense spinal anesthesia while allowing the ability to prolong the block with an epidural catheter. In addition, because the block can be supplemented at any time, the combined spinal-epidural technique allows the use of smaller doses of local spinal anesthetics.[7] In turn, it reduces the incidence of high spinal block and hypotension. In this case, even though we administered a small dose of anesthetics, the level of anesthesia was high. It is because of the shortening and change of spine due to kyphoscoliosis. Consequently it might be better to reduce the dose of anesthetics this kind of patient.

Patients with kyphoscoliosis present unusual challenges for the administration of sedation and anesthesia during surgical procedure. We report this case because we experienced successful anesthesia by using combined epidural-spinal anesthesia during the surgery.

REFERENCES

1. Stoelting RK, Diredorf SF: Anesthesia and co-existing disease. 4th ed. Philadelphia, Churchill Livingstone. 2002, pp 534-35.
2. Stoelting RK, Dierdorf SF: Anesthesia and co-existing diseases. 3rd ed. New York, Churchill-Livingstone. 1993, pp 452-3.
3. Bergofsky EH, Turino GM, Fishman AP: Cardiorespiratory failure in kyphoscoliosis. Medicine 1959; 38: 263-317.
4. Yao FF, Artusio JF Jr: Anesthesiology problem oriented patient management. 2nd ed. Philadelphia, JB Lippincott Company. 1988, pp 654-68.
5. Rom WN, Miller MA: Unexpected longevity in patients with severe kyphoscoliosis. Thorax 1978; 33: 106-10. In: Edited by Murray JF, Nadel JA: Textbook of Respiratory Medicine. 2nd ed. Philadelphia, WB Saunders. 1994, pp 2524-31.
6. Kafer NR. Respiratory and cardiovascular functions in scoliosis and the principles of anesthetic management. Anesthesiology 1980; 52: 339-51.
7. Miller RD: Miller's anesthesia. 6th ed. New York, Churchill Livingstone. 2005, pp 2325.